

# **BioPoly® Great Toe Case Report**

## **Advanced Hallux Rigidus Treated with BioPoly First Metatarsophalangeal Joint Hemi-Arthroplasty: A 14-Month Case Report**

Andrew Kapsalis, DPM - American Health Network, Part of Optum, Greenfield, Indiana

---

### **Case Report**

#### **History of Current Condition**

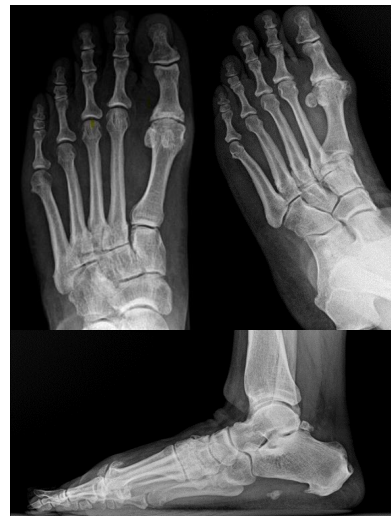A 55-year-old female presented with left foot pain located in the great toe joint. She had limited motion of the joint, which progressed over time. She was able to move the toe in a plantar direction, though had difficulty in bringing it dorsally. There was pain with motion or pressure at the great toe joint. Pain was noticed while in shoes, in open toed sandals, and when barefoot. She had been treated by other foot and ankle specialists over the past 5 plus years for the same issues, and without any significant long-term improvements. She had initial benefits with change in shoe gear, activity modifications, over the counter pain / anti-inflammatory medications. However, these were short-lived and she sought more definitive treatment options. She previously had a more symptomatic hallux valgus deformity on the left foot, which had been treated surgically approximately a year prior to the current issue with the right foot pathology which had progressed to a point where her symptoms limited regular daily activities and available shoe gear.

#### **Notable Past Medical History:**

Hypertension, hyperlipidemia, cervical spine stenosis, previous cerebral aneurysm status post intervention, history of left ankle reconstruction, history of left hallux valgus repair with first tarsometatarsal joint arthrodesis. Her medical conditions were well-controlled.

#### **Physical Examination Findings:**

Neurovascular status was fully intact. There were no open lesions or signs of infection to any location. Left foot and ankle had well-healed surgical locations. The left foot and ankle had no residual pathology or recurrent deformity/pain. The right first metatarsophalangeal joint had a significant dorsal and medial osseous prominence present. There was pain with palpation of this joint dorsally and medially. There was also significantly limited motion of the first metatarsophalangeal joint, measuring at less than 30-40 degrees of maximum dorsiflexion and with an abrupt stop at the end range of dorsiflexion. There was pain with motion of this joint actively and passively. No pain or deformity was appreciated elsewhere. Diagnostic imaging revealed grade 4 hallux rigidus with osteophyte and loose osseous body formation (**Figure 1**).



**Figure 1: Pre-Operative Radiograph**

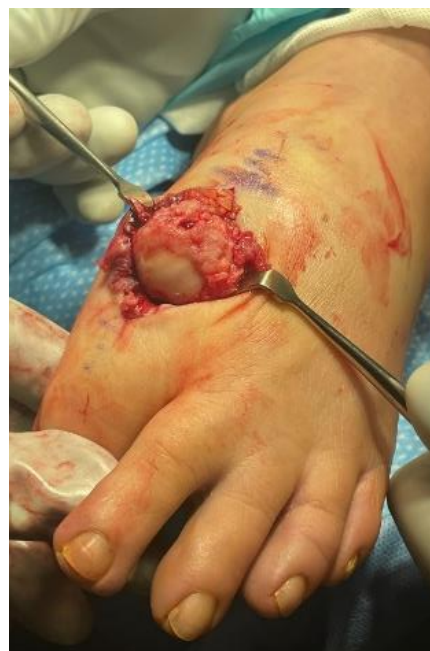### Initial Treatment:

The patient was initially managed with shoe gear modifications, over the counter and prescription pain/anti-inflammatory medications, and R.I.C.E. therapy. She was able to tolerate symptoms with this for approximately 1 year after her initial presentation in this clinic, and about 6+ years of overall conservative care. Her symptoms became progressively more noticeable after resolution of her left foot symptoms with successful surgical intervention. She wished to pursue more definitive treatment with surgical intervention of the right foot. With this, the surgical options for this patient were discussed in great detail. She was offered a first metatarsophalangeal joint arthrodesis or a first metatarsophalangeal joint hemi-arthroplasty with BioPoly Great Toe Implant. The patient was adamant on keeping motion of the great toe joint and opted to proceed with the BioPoly great toe implant.

### Surgical Intervention:

The patient was placed under monitored anesthesia care and an ankle block was performed. An ankle tourniquet was inflated to 250 mmHg.

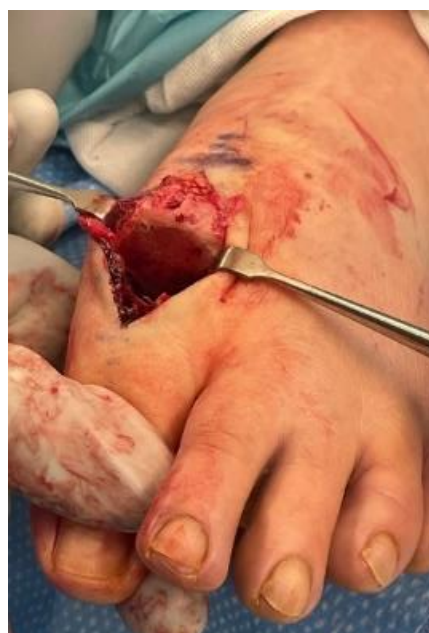A dorsomedial longitudinal incision was performed, followed by atraumatic dissection to the metatarsophalangeal joint capsule. All vital structures and extensor tendons were protected throughout. A dorsal longitudinal capsulotomy was performed and the capsular tissues were gently reflected across the dorsal + medial + lateral metatarsophalangeal joint. A large loose osseous body from the dorsal joint was resected. A McGlamry metatarsal elevator was then introduced into the joint for release of the sesamoid apparatus and constricted plantar capsular tissues. Next, the dorsal osteophyte was removed from the dorsal metatarsal head and the proximal phalanx base locations. This allowed for optimal visualization and access to the joint for next steps in the surgical protocol (**Figure 2**). The metatarsal head had significant degenerative changes, and the proximal phalanx base had a significant amount of adequate cartilage remaining which is important since the BioPoly implant is intended to articulate with cartilage.



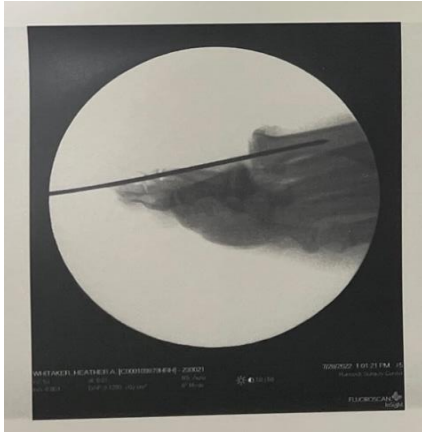
**Figure 2: Joint Exposure**

A 6 mm angulated arthroplasty was performed with a sagittal saw. Adequate subchondral bone was obtained with good cortical margins to the distal metatarsal

(**Figure 3**).

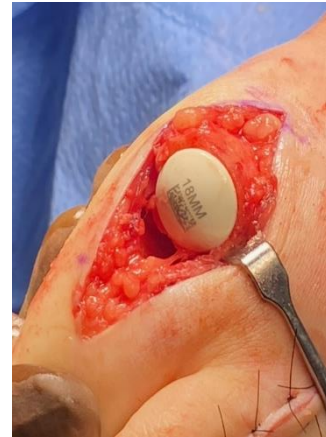

**Figure 4: Metatarsal head osteotomy**



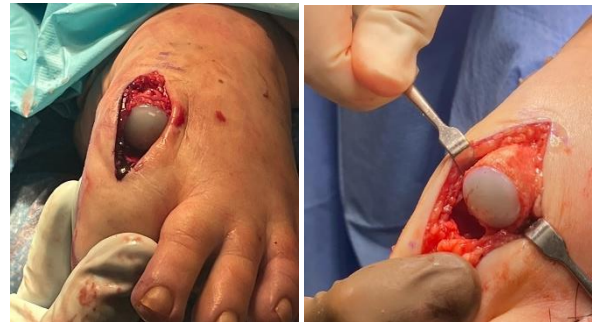**Figure 4: Guide Wire Placement**

A temporary guide wire was applied into the cut surface of the metatarsal for stem placement and initial implant sizing instrumentation (**Figure 4**). The instrumentation confirmed a size 18mm BioPoly implant to be optimal to resurface the metatarsal head as it covered the cut surface without protruding over the edge of the remaining metatarsal head. The appropriate size reamer was applied over the guide wire and utilized to prepare the distal metatarsal for the stem of the implant. After this, the guide wire was removed and an 18 mm trial implant was applied (**Figure 6**). The trial implant fit well, and so all remaining osteophytes and other osseous prominences were resected with a sagittal saw and rongeur until smooth. With resection of all arthritic changes and optimal implant size confirmed, the trial sizer was replaced with the permanent 18 mm BioPoly implant in press fit fashion (**Figure 6**).

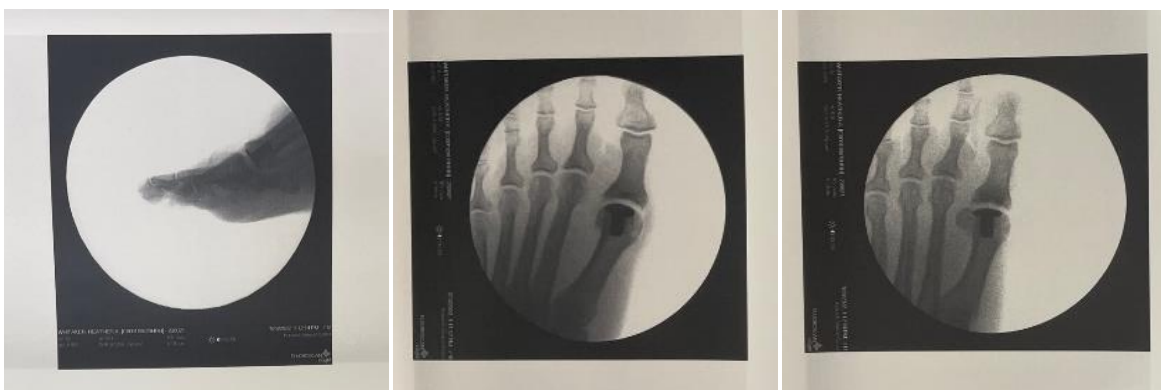


**Figure 5: Trial Implant**

There was appropriate stable fixation obtained with periphery fit to the cortical margins and without any micromotion noted. Intraoperative fluorography confirmed adequate placement of the implant and correction of any previous deformity (**Figure 7**).



**Figure 6: BioPoly Implant**

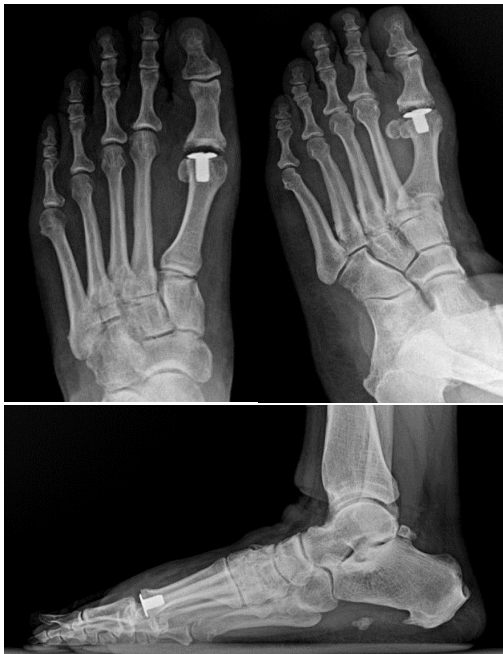

**Figure 7: Intraoperative Fluorography**

The first metatarsophalangeal joint capsule was closed with 3-0 Vicryl. Subcutaneous tissues were reapproximated with 4-0 Monocryl. Skin was reapproximated and closed with 4-0 nylon. Motion testing under clinical and fluorographic examination confirmed supple motion with increased total range of motion compared to preoperative findings. Observed range of motion was noted to have 10 degrees of plantarflexion and 60 degrees of dorsiflexion.

### Outcomes:

This patient was placed into a posterior splint with non-weightbearing recommendations for approximately 2 weeks. Sutures were removed at the 2-week visit, and she was transitioned into a CAM boot with full weightbearing capabilities. She was also educated on a home exercise program to start at this time. She was then progressively weaned out of the CAM boot between postoperative weeks 4 to 6. She was seen at 8 and 12 weeks postop, with resolution of all pain and complete return to regular shoe gear without limitations. She also noticed no restrictions in activity level, with full return to exercising and other activities she had not been able to partake in for



**Figure 8: Post-Operative Radiograph**

years prior to surgery. Her final radiographs showed stable implant placement and correction of her previous deformity (**Figure 8**). She was very happy with the outcomes and stated she would go through this procedure again.

### Discussion:

Osteoarthritis of the first metatarsophalangeal joint (MTPJ) is a common phenomenon that has been reported to occur between 35-65% of patients over 65 years old<sup>11</sup>. Advanced osteoarthritis of this joint was first described as “Hallux Rigidus” by Cottterill in 1887<sup>2</sup>. Hallux rigidus is associated with pain, swelling, stiffness, limited shoe gear, changes in gait pattern, and impactful to quality of life. The well-documented, predictable, and reproducible gold standard of care for hallux rigidus is first MTPJ arthrodesis, which was first popularized by McKeever in 1952<sup>11</sup>. However, first MTPJ arthroplasty procedures with and without implantation devices have been a hopeful treatment option since the 1950s as well<sup>2</sup>. The idea behind arthroplasty is to maintain first ray length, keep or improve joint range of motion, and provide quicker return to unrestricted function.

Although the 1st ray is not axially loaded, procedures at this level still take a massive amount of forces during stance and gait. It has been shown that the 1st ray carries approximately 40-60% of body weight during stance, 2-3 times that of body weight during athletic activities, and up to 8 times that of body weight during running jumps<sup>12</sup>. Due to this, a 1st MTPJ arthrodesis historically has better functional outcomes than joint replacement procedures as seen extensively in literature<sup>5</sup>. Revision rates for arthrodesis can reach as low as 0% in some practices, while revision rates for joint replacements can reach up to 20%<sup>5, 11</sup>. That being said, 1st MTPJ arthroplasty with implantation devices has been extensively shown to provide a high patient satisfaction of 80-97% in the short term<sup>7, 11</sup>. Even further, new implant devices have started to obtain results closer to that of arthrodesis with regards to clinical outcomes, patient satisfaction, reoperation rates, and complication rates when done correctly<sup>13</sup>.

There have been several generations of 1st MTPJ arthroplasty procedures and implantable devices since the early 1950s<sup>11</sup>. The Swanson silastic implants became the mainstay in the late 1960s and early 1970s, and upgraded versions from the 1980s are often still used today<sup>11</sup>. In more recent years, different materials have been utilized to try to solve the problems of the silicone-based implants. These materials usually include cobalt chrome and different polymers. There have also been single and multi-component total joint implants developed. However, to date, the vast majority of implants have all been underwhelming with poor outcomes. Complications have included loosening, subsidence, synovitis, recurrent or new deformities, and even systemic reactions with lymphadenopathy due to implantation failure. Often times, these complications can become life-long problems.

Total toe implants were widely used during the evolution of the 1st MTPJ arthroplasty procedure. The idea was to mimic the implanted devices of other axially loaded joints; however, it has not proven successful. Revision rates of total toe implants are double that of hemi-implant devices (up to 37%), have less functional outcomes scores, have less functional range of motion obtained (33 degrees vs. 43 degrees), and have less overall patient satisfaction<sup>2, 16</sup>. If total toe implants fail, there are large deformities and bone void defects present. Salvage arthrodesis procedures with a structural autograft have good results to correct these problems, though they are not always successful due to high risk of nonunion.

With this, the idea of a hemi-implant has become more popular in recent years. An initially promising product, Cartiva, did not do well in the mid-term and long-term<sup>3, 15</sup>. This was a polyvinyl alcohol first metatarsal implant with minimal osseous resection, though it was found to have dissatisfaction rates over 50% and reoperation rates up to 37.5% within 2 years in some studies<sup>1, 6</sup>. It has also been documented that instability of the implant-bone interface creates an environment for progression of arthritic changes in 100% of patients, along with peri-implant fluid and surrounding bone/soft tissue edema seen on MRI evaluation<sup>1</sup>.

There are newer advancements in partial implants that utilize uncemented metal anchoring surfaces that allow for osteoconduction and osteoinduction capabilities, decreasing osteolysis and aseptic loosening<sup>2</sup>. Biomechanically speaking, newer hemi-implants of the 1st MTPJ have shown better results with restoration of foot posture and medial column loading during gait, as well as improved functional scores and patient satisfaction (95-100%) with minimal to no pain experienced<sup>8, 10, 14</sup>. Survivorship has also improved significantly, with up to 87-100% intact at 2 years and up to 81% at 6 years<sup>8, 9</sup>. This is very promising.

BioPoly Great Toe Implant is a novel 1st metatarsal head hemi-implant device that has shown very encouraging outcomes in the short-term, thus far. There is minimal bone resection needed, allowing for ease of salvage procedures if ever necessary. It has a press-fit porous titanium stem with osteoconduction properties, allowing ease of incorporation with lowered risk of subsidence or aseptic loosening. The cartilage cap is made of a UHMWPE infused with Hyaluronic Acid that has biocompatible and cartilage friendly lubricating properties, which sets it apart from other products. Based on in vitro studies and extensive use of this product material in the knee, survivorship of the implant combined with preservation of native cartilage due to decreased coefficient of friction, show promising results when translated to the 1st MTPJ with high forces across it.

My personal experiences with BioPoly Great Toe Implant are promising. Over the past 14 months, I have performed 7 implants with very positive clinical outcomes in the short-term. No revisions have been needed. No radiographic evidence of loosening has been seen to date. Additional studies are needed to evaluate the mid-term and long-term effectiveness of this implant.

## References

1. An TW, Cassinelli S, Charlton TP, Pfeffer GB, Thordarson DB. Radiographic and Magnetic Resonance Imaging of the Symptomatic Synthetic Cartilage Implant. *Foot Ankle Int.* 2020 Jan;41(1):25-30. doi: 10.1177/1071100719877147. Epub 2019 Sep 20. PMID: 31538827.
2. Barták V, Heřt J, Štědrý J, Popelka S Jr, Popelka S, Hromádka R. Long-term results of total joint arthroplasty and phalangeal hemiarthroplasty of the first metatarsophalangeal joint using the ToeFit Plus™ system. *Foot Ankle Surg.* 2022 Jan;28(1):56-61. doi: 10.1016/j.fas.2021.01.014. Epub 2021 Feb 1. PMID: 33558143.
3. Bernasconi A, De Franco C, Iorio P, Smeraglia F, Rizzo M, Balato G. Use of synthetic cartilage implant (Cartiva®) for degeneration of the first and second metatarsophalangeal joint: what is the current evidence? *J Biol Regul Homeost Agents.* 2020 May-Jun;34(3 Suppl. 2):15-21. ADVANCES IN MUSCULOSKELETAL DISEASES AND INFECTIONS - SOTIMI 2019. PMID: 32856435.
4. Brandao B, Fox A, Pillai A. Comparing the efficacy of Cartiva synthetic cartilage implant hemiarthroplasty vs osteotomy for the treatment of conditions affecting the second metatarsal head. *Foot (Edinb).* 2019 Dec;41:30-33. doi: 10.1016/j.foot.2019.06.003. Epub 2019 Jun 27. PMID: 31675598.
5. Brewster M. Does total joint replacement or arthrodesis of the first metatarsophalangeal joint yield better functional results? A systematic review of the literature. *J Foot Ankle Surg.* 2010 Nov-Dec;49(6):546-52. doi: 10.1053/j.jfas.2010.07.003. Epub 2010 Sep 15. PMID: 20833566.
6. Cassinelli SJ, Chen S, Charlton TP, Thordarson DB. Early Outcomes and Complications of Synthetic Cartilage Implant for Treatment of Hallux Rigidus in the United States. *Foot Ankle Int.* 2019 Oct;40(10):1140-1148. doi: 10.1177/1071100719855049. Epub 2019 Jun 13. PMID: 31195830.
7. Cook E, Cook J, Rosenblum B, Landsman A, Giurini J, Basile P. Meta-analysis of first metatarsophalangeal joint implant arthroplasty. *J Foot Ankle Surg.* 2009 Mar-Apr;48(2):180-90. doi: 10.1053/j.jfas.2008.10.009. Epub 2009 Jan 9. PMID: 19232970.
8. França, G., Nunes, J., Pinho, P., Freitas, D., Andrade, R., Espregueira-Mendes, J., Pereira, B., & Oliva, X. (2020). Is arthrodesis still the best treatment option for first metatarsophalangeal joint arthritis?—a systematic review of arthrodesis and arthroplasty outcomes. *Annals Of Joint*, 6. doi:10.21037/aoj-20-88.
9. Jørsboe PH, Pedersen MS, Benyahia M, Kallemose T, Penny JØ. Mid-Term Functionality and Survival of 116 HemiCAP® Implants for Hallux Rigidus. *J Foot Ankle Surg.* 2021 Mar-Apr;60(2):322-327. doi: 10.1053/j.jfas.2020.10.010. Epub 2020 Nov 4. PMID: 33423889.
10. Jørsboe PH, Speedtsberg MB, Kallemose T, Bencke J, Penny JØ. Plantar forces mid-term after hemiarthroplasty with HemiCAP for hallux rigidus. *Foot Ankle Surg.* 2020 Jun;26(4):432-438. doi: 10.1016/j.fas.2019.05.012. Epub 2019 May 22. PMID: 31153732.
11. Majeed H. Silastic replacement of the first metatarsophalangeal joint: historical evolution, modern concepts and a systematic review of the literature. *EFORT Open Rev.* 2019 Mar 8;4(3):77-84. doi: 10.1302/2058-5241.4.180055. PMID: 30993009; PMCID: PMC6440300.
12. Mao DW, Zheng C, Amatullah NN, Kam C, Kon Kam King C. Salvage arthrodesis for failed first metatarsophalangeal joint arthroplasty: A network meta-analysis. *Foot Ankle Surg.* 2020 Aug;26(6):614-623. doi: 10.1016/j.fas.2019.07.014. Epub 2019 Aug 7. PMID: 31439502.
13. Park YH, Jung JH, Kang SH, Choi GW, Kim HJ. Implant Arthroplasty versus Arthrodesis for the Treatment of Advanced Hallux Rigidus: A Meta-analysis of Comparative Studies. *J Foot Ankle Surg.* 2019 Jan;58(1):137-143. doi: 10.1053/j.jfas.2018.08.045. PMID: 30583775.
14. Rajan RA, Kerr M, Evans H, Outram T. A prospective clinical and biomechanical analysis of feet following first metatarsophalangeal joint replacement. *Gait Posture.* 2021 Sep;89:211-216. doi: 10.1016/j.gaitpost.2021.07.020. Epub 2021 Jul 28. PMID: 34340158.
15. Smyth NA, Murawski CD, Hannon CP, Kaplan JR, Aiyer AA. The Use of a Synthetic Cartilage Implant for Hallux Rigidus: A Systematic Review. *Foot Ankle Spec.* 2021 Aug;14(4):366-371. doi: 10.1177/1938640020937160. Epub 2020 Jul 3. PMID: 32618201.
16. Stibolt RD, Patel HA, Lehtonen EJ, DeBell HA, Moon AS, Naranje S, Shah A. Hemiarthroplasty Versus Total Joint Arthroplasty for Hallux Rigidus: A Systematic Review and Meta-analysis. *Foot Ankle Spec.* 2019 Apr;12(2):181-193. doi: 10.1177/1938640018791017. Epub 2018 Aug 22. PMID: 30132693.